

EP CASE REPORT

Peri-left bundle branch pacing in a patient with right ventricular pacing-induced cardiomyopathy and atrioventricular infra-Hisian block

Shengjie Wu^{1,2†}, Lan Su^{1,2†}, Songjie Wang^{1,2}, Pugazhendhi Vijayaraman³, Kenneth A. Ellenbogen⁴, and Weijian Huang^{1,2*}

¹Department of Cardiology, The First Affiliated Hospital of Wenzhou Medical University, Nanbaixiang, Wenzhou 325000, China; ²The Key Lab of Cardiovascular Disease of Wenzhou, Wenzhou, China; ³Cardiac Electrophysiology, Geisinger Heart Institute, Wilkes Barre, PA, USA; and ⁴Department of Cardiology, Virginia Commonwealth School of Medicine, Richmond, VA, USA

* Corresponding author. Tel: +86 13806691086; fax: +86 577-55578033. E-mail address: weijianhuang69@126.com

† The first two authors are co-first author to the study.

Case report

A 74-years-old man who received a dual-chamber pacemaker with right ventricular (RV) septal pacing due to advanced atrioventricular (AV) block 6 years ago developed a RV pacing-induced cardiomyopathy with left ventricular ejection fraction (LVEF) of 34% and a left ventricular end-diastolic diameter (LVEDd) of 62 mm. We decided to up-grade the RV pacing to a conduction system pacing.

Electrograms obtained from the pacing lead at the His-bundle revealed AV nodal disease with progressive prolongation of A-H interval with dropped His and complete infra-Hisian AV block with dissociation of His and ventricular electrograms (Figure 1A). Pacing at this site

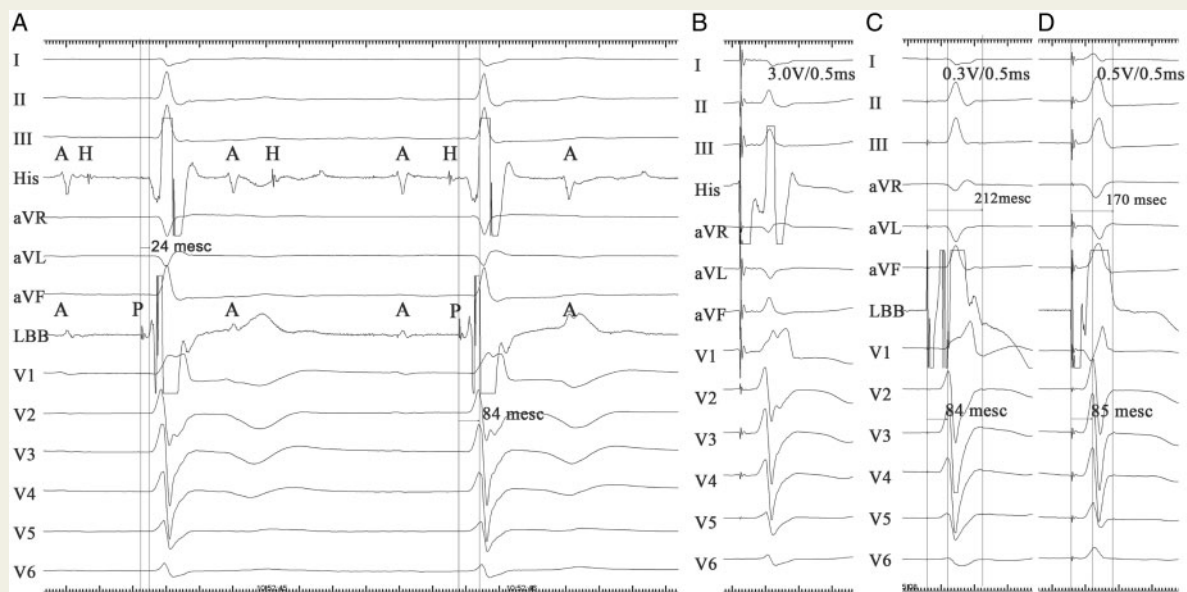


Figure 1 Electrocardiogram from the pacing lead at His site and left bundle branch site. (A) Intrinsic electrocardiogram; (B) His captured at 3 V/0.5 ms; and (C, D) output dependent selective (C) and non-selective LBBP (D) during threshold testing. The stimulus to peak LV activation remained constant. A, atrial wave; H, His potential; LBB, left bundle branch; LBBP, left bundle branch pacing; LV, left ventricle; P, left bundle branch potential.

resulted in His capture with a high threshold of 3.0 V/0.5 ms (Figure 1B) and was considered to be unacceptable. A second lead (Model 3830, Medtronic) was added and moved towards the ventricular side using the proximal His bundle pacing (HBP) lead as a marker to achieve peri-left bundle branch pacing (LBBP).^{1,2} As the lead was advanced deep into the ventricular septum, LBB potential was recorded regularly before each ventricular electrograms (Figure 1A). Unipolar tip pacing resulted in a paced QRS of right bundle branch block (RBBB) morphology and achieved selective LBBP at the threshold of 0.3 V/0.5 ms and local myocardial capture at the output of 0.5 V/0.5 ms with similar stimulus to peak left ventricular (LV) activation time of 84 ms (Figure 1C and D). There was 1:1 LBB-ventricular conduction at pacing rates of 150 b.p.m. The R-wave amplitude was 19.7 mv.

A cardiac resynchronization therapy pacemaker was implanted with right atrial (A) lead connected to the A-port, LBB lead connected to the RV-port, and the coronary sinus (CS) lead connected to the LV-port. We chose LBB area as the primary site of pacing with LV pacing delayed in the refractory period, and then turn off when a stable threshold was confirmed. After 6 months of LBBP with a paced QRS of RBBB morphology, LVEF increased to 63%, LVEDd decreased to 46 mm, and New York Heart Association class improved from III to I. The LBB capture threshold was 0.5 V/0.5 ms and R-wave amplitude was 20 mV.

Discussion

Left bundle branch pacing, pacing immediately beyond the site of block, would be an excellent alternative to HBP in patients with distal His disease or in whom optimal His capture threshold cannot be achieved.^{2,3} The following tips help confirm whether the lead is adjacent to LBB: (i) recording a constant LBB potential regularly before the V electrogram suggests that the lead is adjacent to LBB and beyond the site of block; (ii) output dependent selective and non-selective LBBP is a direct evidence for LBB capture; and (iii) once the LBB is captured, the stimulus to peak LV activation time remains constant due to rapid conduction via His-Purkinje system.

With further clinical and methodological investigations, LBBP will make conduction system pacing more widely applicable.

Funding

Key Research and Development Program of Zhejiang [2019C03012] and Major Project of the Science and Technology of Wenzhou [ZS2017010].

Conflict of interest: none declared.

References

1. Su L, Wu S, Wang S, Wang Z, Xiao F, Shan P *et al.* Parameters and success rates of permanent His bundle pacing in patients with narrow QRS: a single center experience. *Europace* 2018;doi:10.1093/europace/euy281.
2. Huang W, Su L, Wu S, Xu L, Xiao F, Zhou X *et al.* A novel pacing strategy with low and stable output: pacing the left bundle branch immediately beyond the conduction block. *Can J Cardiol* 2017;**33**:1736.e1731–3.
3. Huang W, Su L, Wu S, Xu L, Xiao F, Zhou X *et al.* Long-term outcomes of His bundle pacing in patients with heart failure with left bundle branch block. *Heart* 2019;**105**:137–43.